

Bite force in children with unilateral crossbite before and after orthodontic treatment. A prospective longitudinal study

Liselotte Sonnesen* and Merete Bakke**

Departments of *Orthodontics and **Oral Medicine, School of Dentistry, Faculty of Health Sciences, University of Copenhagen, Denmark

SUMMARY In this prospective, longitudinal study, bite force was examined in children with a unilateral posterior crossbite before (stage 1), immediately after orthodontic treatment (stage 2), and after retention (stage 3). The sample comprised 19 (7 girls, 12 boys) children aged 7–11 years. The children were treated according to conventional practice, with an expansion plate (seven subjects) or a quadhelix appliance (12 subjects). Unilateral bite force was measured at the first molars by means of a standardized method. Statistical analysis was undertaken using Shapiro–Wilks W - and t -tests, and analysis of variance.

There was no significant difference in bite force regarding age, gender, appliance, or side, i.e. right or left molar region. However, during stage 2 the bite force was significantly lower ipsilaterally to the crossbite than contralaterally ($P < 0.05$). In general, the bite force was systematically lower than reference values, but the mean bite force ($P < 0.05$) and the bite force on the ipsilateral side ($P < 0.01$) increased significantly from stage 2 to stage 3.

The bite force level was reduced immediately after treatment, but increased again after retention and approached the bite force level in children with neutral occlusion. The fluctuation in bite force level during orthodontic treatment may be due to transient changes in occlusal support, periodontal mechanoreceptors, and jaw elevator muscle reflexes.

Introduction

Posterior crossbite occurs in 8–17 per cent of the population, most often unilaterally with a neuromuscular guidance of the mandible towards the crossbite side (Helm, 1968, 1970; Foster and Hamilton, 1969; Kutin and Hawes, 1969; Troelstrup and Møller, 1970; Day and Foster, 1971; Ingervall *et al.*, 1972; Thilander and Myrberg, 1973; Ravn, 1975; Kisling and Krebs, 1976; Kerosuo *et al.*, 1991).

Previous studies have found that this malocclusion trait is associated with asymmetrical muscular function (Troelstrup and Møller, 1970; Ingervall and Thilander, 1975; Michler *et al.*, 1987; Ferrario *et al.*, 1999) that affects the development of the elevator muscles in terms of muscle masseter thickness (Kiliaridis *et al.*, 2000) and bite force (Sonnesen *et al.*, 2001a). Bite force is reported to be a key predictor for masticatory performance (Hatch *et al.*, 2001) and a large bite force has been found to cause a high masticatory performance, especially when chewing hard food (Okiyama *et al.*, 2003). Furthermore, some studies have shown a unilateral posterior crossbite to be statistically associated with symptoms and signs of temporomandibular disorders (TMD), such as pain, headache, and muscle tenderness (Egermark-Eriksson *et al.*, 1983, 1990; Brandt, 1985; Riolo *et al.*, 1987; Kritsineli and Shim, 1992; Sonnesen *et al.*, 1998, 2001a), which may also be related to activity and performance of masticatory muscles. No previous prospective and longitudinal study in children has described the outcome of orthodontic treatment of a unilateral crossbite with respect to bite force.

Therefore, the aim of the present study was to compare the maximum molar bite force in children with a unilateral posterior crossbite before, immediately after orthodontic treatment, and after retention.

Subjects

Nineteen Caucasian children with a unilateral posterior crossbite were recruited for this study. Ten had a crossbite on the right side and nine a left-sided crossbite. The group consisted of 7 girls and 12 boys aged 7–11 years (mean 9.9 years), sequentially admitted for orthodontic treatment at the Municipal Dental Health Service in Lyngby, North Zealand, Denmark, and selected using the Danish procedure for screening the child population for malocclusions entailing health risks (Danish Ministry of Health, 1990; Solow, 1995). In all children, the unilateral crossbite was accompanied by deviation of the lower dental arch midline to the crossbite side. None of the children had craniofacial anomalies or systemic muscle or joint disorders, and in none of the children were the signs and symptoms of TMD so severe that they needed TMD treatment. The children were followed before treatment (stage 1, mean age 9.9 years, range 7–11 years), immediately after orthodontic treatment (stage 2, i.e. after 7 months, mean age 10.6 years, range 7–12 years), and after retention (stage 3, i.e. 4–6 months after orthodontic treatment, mean age 11.0, range 8–13 years).

Methods

Registration of occlusion

The occlusion was diagnosed by one author (LS) according to Björk *et al.* (1964). A unilateral crossbite was recorded for the canine, the premolar, and the molar section, if the buccal cusp of the upper tooth occluded lingually to the buccal cusp of the corresponding lower tooth. The registration was made if at least one tooth was deviated and the child needed orthodontic treatment according to the above-mentioned criteria.

Treatment methods and stages

The orthodontic treatment, including the choice of appliance, was chosen according to conventional practice after an overall evaluation of the child, including an assessment of cooperation by two specialists in orthodontics (L.S. and B. Nybølle). Seven children were treated with an expansion plate and 12 with a quadhelix.

The expansion plate was worn 24 hours a day, except when eating or brushing the teeth, and during the active treatment, the patient was asked to turn the screw twice a week. During the 6-month retention period, the plate was worn only at night. The mean age before treatment was 9.6 years, immediately after treatment 10.2 years, and after retention 10.7 years.

The quadhelix was activated once every 6–8 weeks during active treatment. During the 4-month retention period, the quadhelix remained in the mouth. The mean age before treatment was 10.1 years, immediately after treatment 10.8 years, and after retention 11.1 years.

Bite force

In order to assess the strength of the mandibular elevator muscles, the maximum unilateral bite force was measured during all three stages by one author (LS). The recordings were made at the first mandibular molars on each side by means of a pressure transducer (Flöystrand *et al.*, 1982) during 1–2 seconds of maximum clenching, according to a standard procedure described by Bakke *et al.* (1989). Only in one subject, a boy at stage 2, was the bite force measurement associated with discomfort/light pain and consequently his force value was not included.

The reliability of the bite force measurements has previously been assessed by double recordings on 23 randomly selected children with an interval of 14 days (Sonnesen *et al.*, 2001b) without significant difference between the two sets of measurements and with the method error [$S(i)$] of the individual double recordings with 2-week intervals of 6 per cent. The coefficient of reliability was 0.91.

Statistical analysis

The bite force values did not deviate from the normal distribution assessed using the parameters of skewness and

kurtosis and by Shapiro–Wilks W -test. For bite force, the effects of age and gender were assessed by linear regression analyses. Differences in the means of bite force between appliances and sides were assessed by unpaired t -test. A two-way analysis of variance (ANOVA) and a Bonferroni correction test were performed to compare the bite force at the three stages. The results were considered to be significant at values below $P < 0.05$ and the analyses were performed using the Statistical Package for Social Sciences, version 13.0 (SPSS Inc., Chicago, Illinois, USA)

Results

There was no significant difference in bite force regarding age, gender, or appliance, and no significant differences between the right and left sides. Therefore, values from boys and girls with plate or quadhelix treatment and a right or left side crossbite were pooled. Regarding the crossbite side, i.e. ipsilateral, and non-crossbite side, i.e. contralateral, the bite force was significantly lower on the ipsilateral side than on the contralateral side, but only in stage 2 ($P < 0.05$). The mean bite force and the bite force on the ipsilateral side increased significantly from stage 2 to 3 ($P < 0.05$ and $P < 0.01$, respectively; Table 1, Figure 1).

The bite force at the three stages was systematically lower than the mean level in a reference material consisting of children with neutral occlusion (Sonnesen *et al.*, 2001a), but within the 95 per cent confidence limit of the reference material. After retention (stage 3), the bite force was closer to the mean bite force level in the children with neutral occlusion (Figure 1).

Discussion

In agreement with previous studies for the young children, there was no difference in bite force between gender (Lindquist and Ringqvist, 1973; Helle *et al.*, 1983; Kiliaridis *et al.*, 1993) or between right and left side (Lindquist and Ringqvist, 1973; Helle *et al.*, 1983; Bakke *et al.*, 1989; Shiau and Wang, 1993; Ingervall and Minder, 1997). Corresponding with the previous findings of different

Table 1 Maximum molar bite force (N) for the crossbite and non-crossbite side.

Bite force (SD)	Stage 1	Stage 2	Stage 3	ANOVA
	Before treatment	After expansion	After retention	P
Crossbite side	284.21 (64.84)	245.89 (68.41)	338.26 (94.95)	**
Non-crossbite side	302.16 (88.36)	274.06 (78.31)	321.42 (91.19)	
Mean	293.18 (67.33)	259.97 (68.44)	329.84 (84.68)	*

* $P < 0.05$ (increase in bite force from stage 2 to 3);

** $P < 0.01$ (increase in bite force from stage 2 to 3);

SD, standard deviation, ANOVA, analysis of variance.

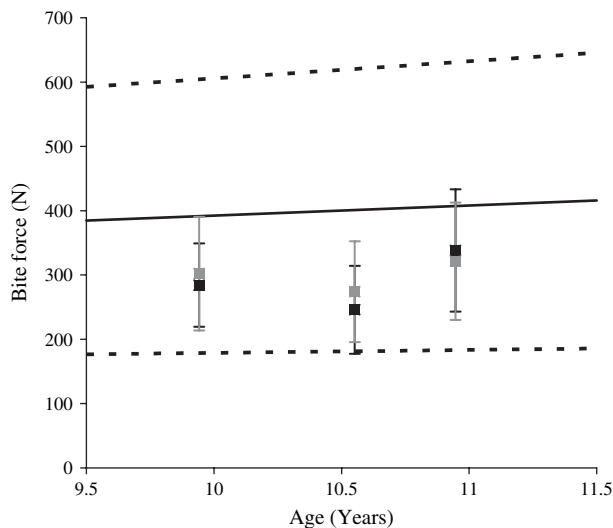


Figure 1 Mean bite force level in the three stages (black box, crossbite side; grey box, non-crossbite side) and in children with neutral occlusion (solid line, regression line; dotted line, 95 per cent confidence interval).

masseter volume, ipsilateral and contralateral to the crossbite (Kiliaridis *et al.*, 2000), different bite force values may also have been expected although elevator muscles on both sides are activated during bite force measurements (Bakke *et al.*, 1989). However, only immediately after treatment was bite force significantly lower on the ipsilateral side than on the contralateral side. With the insignificant pre-treatment difference between sides, this could be due to a degeneration of the axons in the periodontal ligament after application of orthodontic forces, as observed in experimental studies in cats (Long *et al.*, 1996). More likely, it could be caused by reduced occlusal support with fewer tooth contacts on the crossbite side immediately after treatment, since the level of elevator muscle activity and the magnitude of bite force is strongly associated with occlusal support (Bakke *et al.*, 1993). The increased bite force level after the retention period could support this idea. In addition, transient changes in masseteric reflex responses have been seen in subjects treated with functional appliances for Class II division I malocclusions, probably originating in periodontal and muscular receptors (Carels and van Steenberghe, 1986). Further, the condyle and fossa were probably not yet fully adapted to the new position of the mandible immediately after treatment (Thilander, 1985; Hesse *et al.*, 1997; Lam *et al.*, 1999; Nerder *et al.*, 1999).

After retention, the bite force increased, which may be associated with normalization of the threshold of the periodontal mechanoreceptors as reported after experimental orthodontic tooth movements in rats (Nakanishi *et al.*, 2004). The bite force in the studied children was then closer to the bite force level in children with neutral occlusion, but still below the mean level. No pain adaptation reducing jaw elevator muscle contraction could account for the low bite force immediately after treatment, but a type of adaptation

or 'retraining' of the elevator muscles probably takes place during and after treatment (Bakke, 1993). However, as the treatment was started in the late mixed dentition (mean age 9.9 years), it may also be difficult to normalize the muscular function completely (Hamerling *et al.*, 1991; Ben-Bassat *et al.*, 1993; de Boer and Steenks, 1997; Thilander and Lennartsson, 2002).

Conclusion

The bite force in children with a unilateral crossbite was systematically lower than the mean level of children with neutral occlusion, but within the 95 per cent confidence limit. The bite force level was lowest immediately after orthodontic treatment probably due to transient changes in occlusal support, periodontal mechanoreceptors, and jaw elevator muscle reflexes, but the bite force increased again after retention and approached the mean bite force level in children with neutral occlusion.

Address for correspondence

Liselotte Sonnesen
Department of Orthodontics
School of Dentistry
20 Nørre Allé
DK-2200 Copenhagen N
Denmark
E-mail: lls@odont.ku.dk

Acknowledgements

We extend sincere thanks to the patients and staff in the orthodontic clinic at the Municipal Dental Health Service in Lyngby, especially Dr B. Nybølle and dental nurse, Mrs L. Nielsen. Dr L. T. Skovgaard, Department of Biostatistics, University of Copenhagen, provided valuable professional assistance in the design of the statistical analysis.

References

- Bakke M 1993 Mandibular elevator muscles: physiology, action, and effect of the dental occlusion. *Scandinavian Journal of Dental Research* 101: 314–351
- Bakke M, Michler L, Han K, Möller E 1989 Clinical significance of isometric bite force versus electrical activity in temporal and masseter muscles. *Scandinavian Journal of Dental Research* 97: 539–551
- Bakke M, Stolze K, Tuxen A 1993 Variables related to masseter muscle function: a maximum R2 improvement analysis. *Scandinavian Journal of Dental Research* 101: 159–165
- Ben-Bassat Y, Yaffe A, Brin I, Freeman J, Ehrlich Y 1993 Functional and morphological-occlusal aspects in children treated for unilateral posterior cross-bite. *European Journal of Orthodontics* 15: 57–63
- Björk A, Krebs Å, Solow B 1964 A method for epidemiological registration of malocclusion. *Acta Odontologica Scandinavica* 22: 27–41
- Brandt D 1985 Temporomandibular disorders and their association with morphologic malocclusion in children. In: Carlson D S, McNamara J A,

- Ribbens K A (eds) Developmental aspects of temporomandibular joint disorders. Monograph No. 16, Craniofacial Growth Series. Center for Human Growth and Development, University of Michigan, Ann Arbor, pp. 279–298
- Carels C, van Steenberghe D 1986 Changes in neuromuscular reflexes in the masseter muscles during functional jaw orthopedic treatment in children. *American Journal of Orthodontic and Dentofacial Orthopedics* 90: 410–419
- Danish Ministry of Health (Order No. 338) 1990 Bekendtgørelse om kommunal tandpleje. Schultz Grafisk A/S, Copenhagen
- Day A J W, Foster T D 1971 An investigation into the prevalence of molar crossbite and some associated aetiological conditions. *Dental Practitioner and Dental Record* 21: 402–410
- de Boer M, Steenks M H 1997 Functional unilateral posterior crossbite. Orthodontic and functional aspects. *Journal of Oral Rehabilitation* 24: 614–623
- Egermark-Eriksson I, Ingervall B, Carlsson G E 1983 The dependence of mandibular dysfunction in children on functional and morphologic malocclusion. *American Journal of Orthodontics* 83: 187–194
- Egermark-Eriksson I, Carlsson G E, Magnusson T, Thilander B 1990 A longitudinal study on malocclusion in relation to signs and symptoms of cranio-mandibular disorders in children and adolescents. *European Journal of Orthodontics* 12: 399–407
- Ferrario V F, Sforza C, Serrao G 1999 The influence of crossbite on the coordinated electromyographic activity of human masticatory muscles during mastication. *Journal of Oral Rehabilitation* 26: 575–581
- Fløystrand F, Kleven E, Öilo G 1982 A novel miniature bite force recorder and its clinical application. *Acta Odontologica Scandinavica* 40: 209–214
- Foster T D, Hamilton M C 1969 Occlusion in the primary dentition. *British Dental Journal* 126: 76–79
- Hamerling K, Naeije C, Myrberg N 1991 Mandibular function in children with a lateral forced bite. *European Journal of Orthodontics* 13: 35–42
- Hatch J P, Shinkai R S A, Sakai S, Rugh J D, Paunovich E D 2001 Determinants of masticatory performance in dentate adults. *Archives of Oral Biology* 46: 641–648
- Helle A, Tulensalo T, Ranta R 1983 Maximum bite force values of children in different age groups. *Proceeding of the Finnish Dental Society* 79: 151–154
- Helm S 1968 Malocclusion in Danish children with adolescent dentition: an epidemiologic study. *American Journal of Orthodontics* 54: 352–366
- Helm S 1970 Prevalence of malocclusion in relation to development of the dentition. An epidemiological study of Danish school children. *Acta Odontologica Scandinavica* 28 (Supplement 58):1
- Hesse K L, Årtun J, Joondeph D R, Kennedy D B 1997 Changes in condylar position and occlusion associated with maxillary expansion for correction of functional unilateral posterior crossbite. *American Journal of Orthodontics and Dentofacial Orthopedics* 111: 410–418
- Ingervall B, Minder C 1997 Correlation between maximal bite force and facial morphology in children. *Angle Orthodontist* 67: 415–422
- Ingervall B, Thilander B 1975 Activity of temporal and masseter muscles in children with a lateral forced bite. *Angle Orthodontist* 45: 249–258
- Ingervall B, Seeman L, Thilander B 1972 Frequency of malocclusion and need of orthodontic treatment in 10-year-old children in Gothenburg. *Swedish Dental Journal* 65: 7–21
- Kerosuo H, Laine T, Nyssönen V, Honkala E 1991 Occlusal characteristics in groups of Tanzanian and Finnish urban schoolchildren. *Angle Orthodontist* 61: 49–56
- Kiliaridis S, Kjellberg H, Wenneberg B, Engström C 1993 The relationship between maximal bite force, bite force endurance, and facial morphology during growth. A cross-sectional study. *Acta Odontologica Scandinavica* 51: 323–331
- Kiliaridis S, Katsaros C, Raadsheer M C, Mahboubi P H 2000 Bilateral masseter muscle thickness in growing individuals with unilateral crossbite. *Journal of Dental Research* 79: 497(abstrakt)
- Kisling E, Krebs G 1976 Pattern of occlusion in 3-year-old Danish children. *Community Dentistry and Oral Epidemiology* 4: 152–159
- Kritsineli M, Shim Y S 1992 Malocclusion, body posture, and temporomandibular disorder in children with primary and mixed dentition. *Journal of Clinical Pediatric Dentistry* 16: 86–93
- Kutin G, Hawes R R 1969 Posterior cross-bite in the deciduous and mixed dentitions. *American Journal of Orthodontics* 56: 491–504
- Lam P H, Sadowsky C, Omerza F 1999 Mandibular asymmetry and condylar position in children with unilateral posterior crossbite. *American Journal of Orthodontics and Dentofacial Orthopedics* 115: 569–575
- Lindquist B, Ringqvist M 1973 Bite force in children with bruxism. *Acta Odontologica Scandinavica* 31: 255–259
- Long A, Loescher A R, Robinson P P 1996 A histological study on the effect of different periods of orthodontic force on the innervation and dimensions of the cat periodontal ligament. *Archives of Oral Biology* 41: 799–808
- Michler L, Bakke M, Møller E 1987 Graphic assessment of natural mandibular movements. *Journal of Craniomandibular Disorders: Facial & Oral Pain* 1: 97–114
- Nakanishi H, Seki Y, Kohne T, Muramoto T, Toda K, Soma K 2004 Changes in response properties of periodontal mechanoreceptors after experimental orthodontic tooth movements in rats. *Angle Orthodontist* 74: 93–99
- Nerder L, Bakke M, Solow B 1999 The functional shift of the mandible in unilateral posterior crossbite and the adaptation of the temporomandibular joints: a pilot study. *European Journal of Orthodontics* 21: 155–166
- Okiyama A, Ikebe K, Nokubi T 2003 Association between masticatory performance and maximal occlusal force in young men. *Journal of Oral Rehabilitation* 30: 278–282
- Ravn J J 1975 Occlusion in the primary dentition in 3-year-old children. *Scandinavian Journal of Dental Research* 83: 123–130
- Riolo M L, Brandt D, TenHave T R 1987 Associations between occlusal characteristics and signs and symptoms of TMJ dysfunction in children and young adults. *American Journal of Orthodontics and Dentofacial Orthopedics* 92: 467–477
- Shiau Y-Y, Wang J-S 1993 The effects of dental condition on hand strength and maximum bite force. *Cranio: The Journal of Craniomandibular Practice* 11: 48–54
- Solow B 1995 Guest editorial: orthodontic screening and third party financing. *European Journal of Orthodontics* 17: 79–83
- Sonnesen L, Bakke M, Solow B 1998 Malocclusion traits and symptoms and signs of temporomandibular disorders in children with severe malocclusion. *European Journal of Orthodontics* 20: 543–559
- Sonnesen L, Bakke M, Solow B 2001a Bite force in pre-orthodontic children with unilateral crossbite. *European Journal of Orthodontics* 23: 741–749
- Sonnesen L, Bakke M, Solow B 2001b Temporomandibular disorders in relation to craniofacial dimensions, head posture, and bite force in children selected for orthodontic treatment. *European Journal of Orthodontics* 23: 179–192
- Thilander B 1985 Temporomandibular joint problems in children. In: Carlson D S, McNamara J A (eds) Developmental aspects of temporomandibular joint disorders. Monograph No. 16, Craniofacial Growth Series. Center for Human Growth and Development, University of Michigan, Ann Arbor, pp. 89–104
- Thilander B, Lennartsson B 2002 A study of children with unilateral posterior crossbite, treated and untreated, in the deciduous dentition occlusal and skeletal characteristics of significance in predicting the long-term outcome. *Journal of Orofacial Orthopedics* 63: 371–383
- Thilander B, Myrberg N 1973 The prevalence of malocclusion in Swedish schoolchildren. *Scandinavian Journal of Dental Research* 81: 12–21
- Troelstrup B, Møller E 1970 Electromyography of the temporalis and masseter muscles in children with unilateral cross-bite. *Scandinavian Journal of Dental Research* 78: 425–430